Anesthesia Considerations in Glaucoma Surgery

Paul M Munden, MD MBA

Oklahoma VA Health Care System

PREVIEW

- Pertinent ocular and orbital anatomy
- The glaucoma damaged optic nerve
- Pre-operative factors
- Modification of common methods of ocular anesthesia
- Considerations for specific procedures

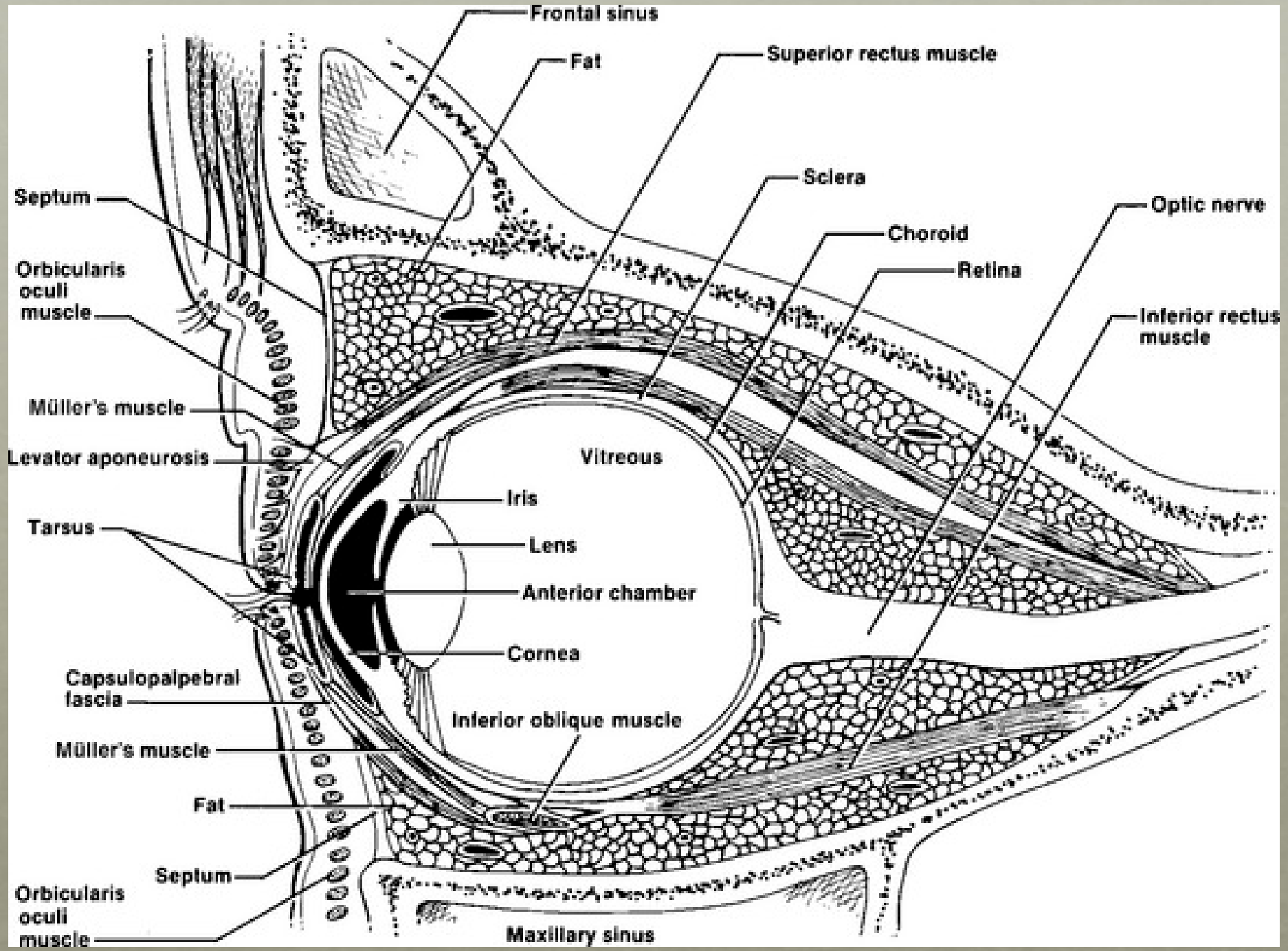
Frontal sinus
Fat
Superior rectus muscle
Sclera
Choroid
Retina
Optic nerve
Inferior rectus muscle
Septum
Orbicularis oculi muscle
Müller's muscle
Levator aponeurosis
Vitreous
Iris
Lens
Tarsus
Anterior chamber
Cornea
Capsulopalpebral fascia
Inferior oblique muscle
Müller's muscle
Fat
Septum
Orbicularis oculi muscle
Maxillary sinus

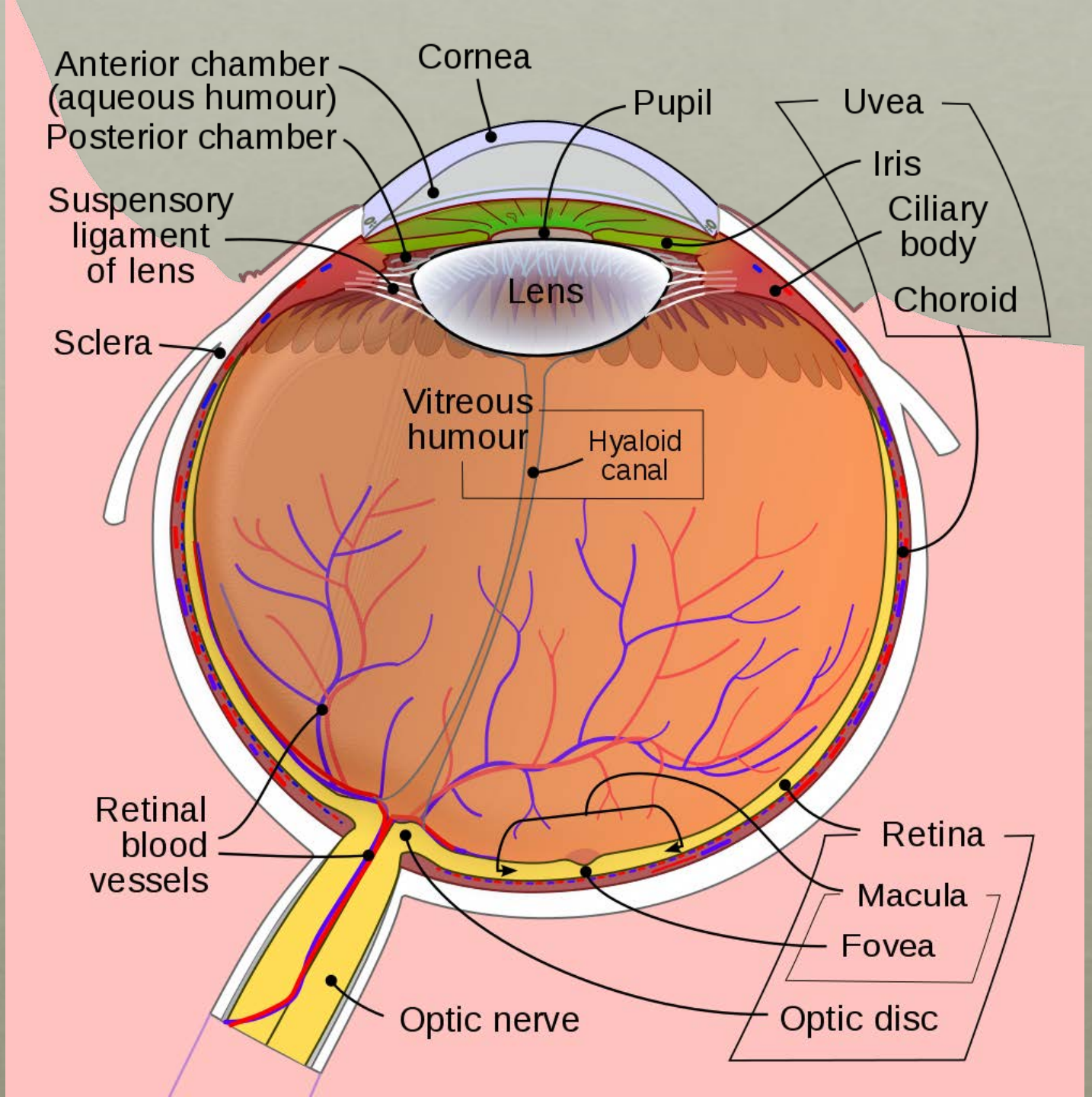
Anterior chamber
(aqueous humour)
Posterior chamber
Cornea
Pupil
Uvea
Iris
Ciliary
body
Choroid
Suspensory
ligament
of lens
Lens
Sclera
Vitreous
humour
Hyaloid
canal
Retinal
blood
vessels
Retina
Macula
Fovea
Optic nerve
Optic disc

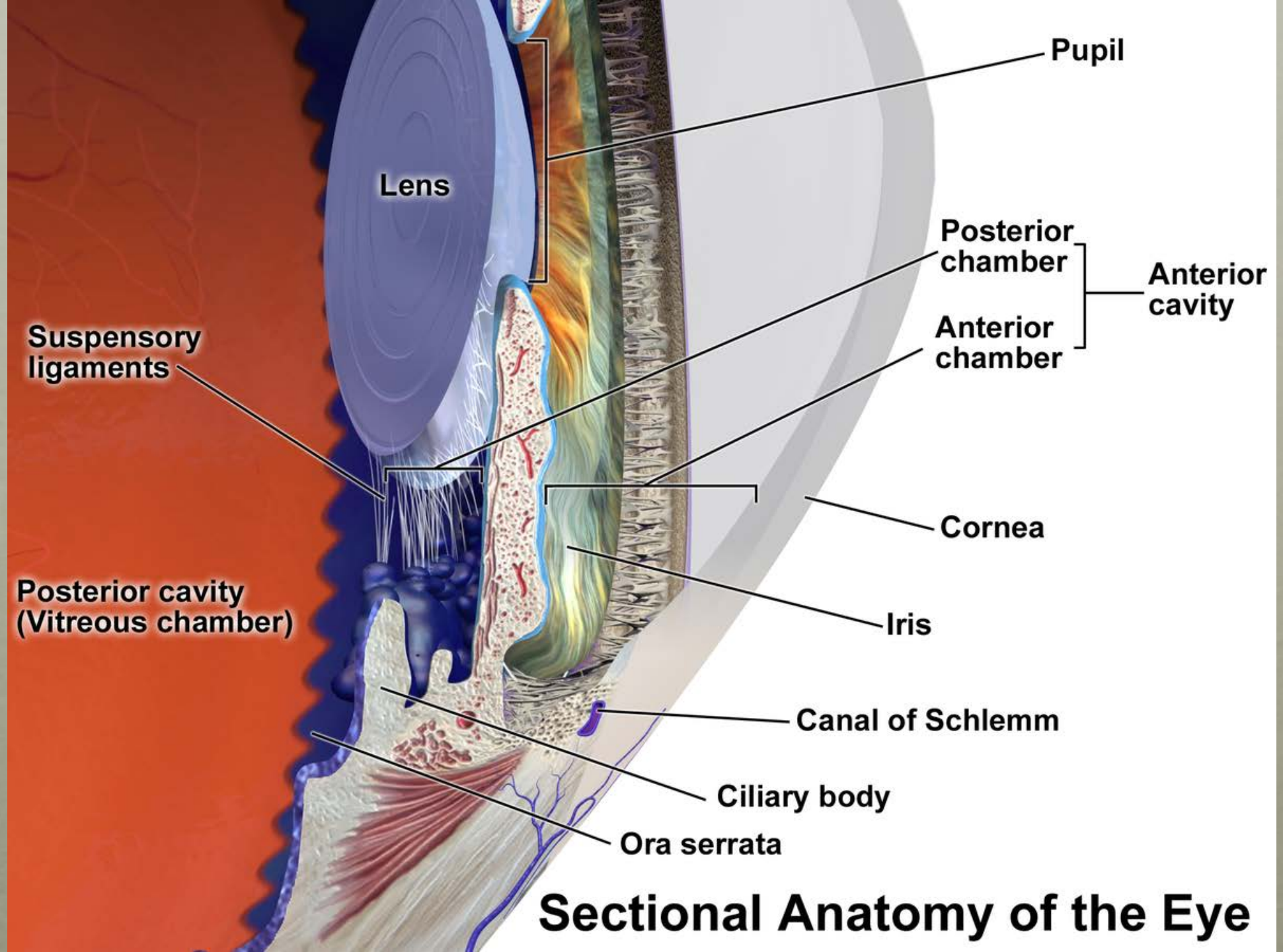
Pupil
Lens
Posterior chamber
Anterior cavity
Anterior chamber
Suspensory ligaments
Cornea
Posterior cavity (Vitreous chamber)
Iris
Canal of Schlemm
Ciliary body
Ora serrata
Sectional Anatomy of the Eye

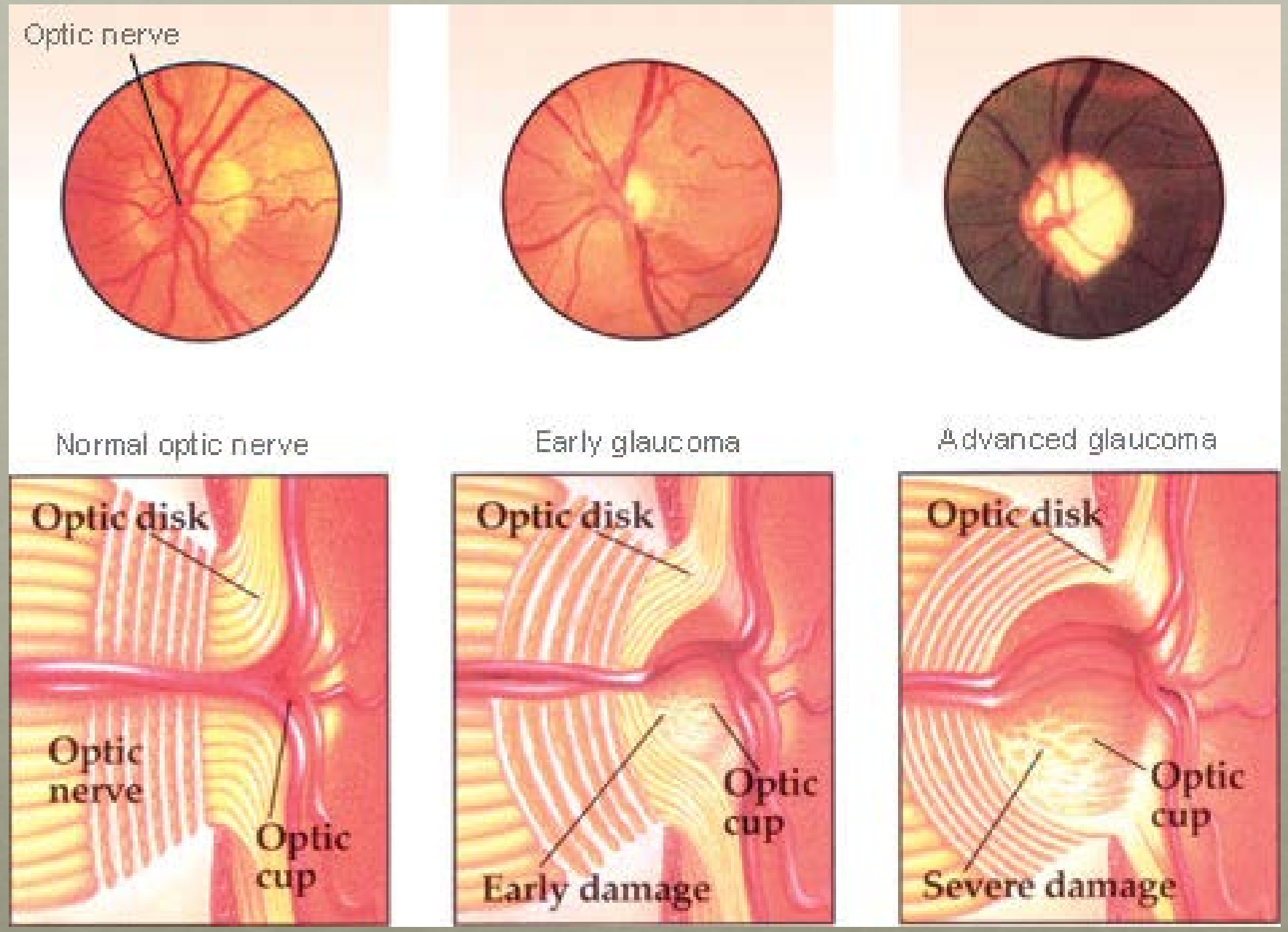
Optic nerve
Normal optic nerve
Early glaucoma
Advanced glaucoma
Optic disk
Optic nerve
Optic cup
Optic disk
Optic cup
Early damage
Optic disk
Optic cup
Severe damage

COMPROMISED OPTIC NERVE

- Mechanical compression
  - Mass Effect
    - Retrobulbar hemorrhage
    - Hyaluronidase orbitopathy
- Perfusion
  - Compartment syndrome with local block
  - Optic nerve perfusion
    - Perfusion pressure/hypotension
    - Oxygenation
    - Oxygen carrying capacity
- Interruption of nerve transmission
  - RBB, sub-Tenons, infiltration

Anesthetic Objectives
Glaucoma Surgery

- Anesthesia
  - Absence of pain/discomfort
- Amnesia
  - Absence of memory
- Akinesia
  - Absence of surgeon anxiety

Surgeon-Anesthesia Provider

Glaucoma Surgery

- Communication
  - Pre-operative considerations
  - Intra-operative interventions
  - Post-operative requirements

INDIVIDUALIZATION
GLAUCOMA SURGERY

- Dictates anesthetic choices
- Physical requirements
  - Patient positioning
- Emotional requirements
  - Anxiety
- Surgeon requirements
  - Angle surgery
  - Patient movement
  - Reverse Trendelenberg position
  - ”Open eye”
    - Valsalva, “bucking”

SYSTEMIC MEDICATIONS
GLAUCOMA SURGERY

- Anticoagulants
- Antiplatelet agents
  - Retrobulbar hemorrhage
  - Choroidal hemorrhage
  - Hyphema
  - Subconjunctival hemorrhage
  - "For more complex [non-cataract] surgery with a higher risk of bleeding, anticoagulants and antiplatelet agents may compromise surgical outcome and influence the choice of anesthesia. Currently, there is insufficient evidence to make anesthesia-specific recommendations regarding continuation or cessation of these drugs. Each patient and procedure should be treated on its own merits with multi-disciplinary input as required".
    - Royal College of Ophthalmologists & Royal College of Anaesthetists. Local Anaesthesia for Ophthalmic Surgery. (Internet). London, 2012 Feb. p. 38.

Topical Medications
Glaucoma Surgery

- Beta blockers
  - Bradycardia/bronchospasm
- Alpha adrenergic agonists
  - Brimonidine crosses blood-brain barrier
  - Hypotension
  - Somnolence in children
- Acetazolamide (Oral CAI)
  - Hypokalemia
  - Metabolic acidosis
- Ecothiophate Iodide
  - Binds irreversibly to cholinesterase
  - D/C 6 weeks before GA with succinylcholine
  - Pralidoxime antidote

Anesthetic Techniques
Glaucoma Surgery

- Sedation
- Topical
- Local
- General
  - Inhalational
  - Ketamine

Sedation
Glaucoma Surgery

- Fentanyl
  - Paradoxical reaction
  - Chest wall rigidity
- Midazolam
  - Disinhibition
- Propofol

TOPICAL
GLAUCOMA SURGERY

- Proparacaine 0.5%
  - Amino ester, shorter acting
- Tetracaine 0.5%
  - Amino ester, longer acting
- Lidocaine liquid and gel
- Intracameral
  - 1% to 4% non-preserved lidocaine
- Shugarcaine
  - Preservative, bisulfite-free 1:1000 epinephrine
  - 4% non-preserved lidocaine
  - BSS plus to buffer

Topical Disadvantages

- Eye movement
  - Especially problematic with angle based procedures
- Photophobia
- May need repeated administration with longer procedure

LOCAL
GLAUCOMA SURGERY

- Retrobulbar block
  - Shorter acting faster onset + longer acting slower onset
  - Orbital compartment syndrome in eye with compromised optic nerve
- Peribulbar
- Sub-Tenon's
  - Prior to or during procedure
- Agents
  - Avoid epinephrine around optic nerve
  - Hyaluronidase orbitopathy

LOCAL - COMPLICATIONS

- Brainstem Anesthesia
- Direct optic nerve injury
  - Hemorrhage/hematoma
- Globe perforation
- Retobulbar hemorrhage

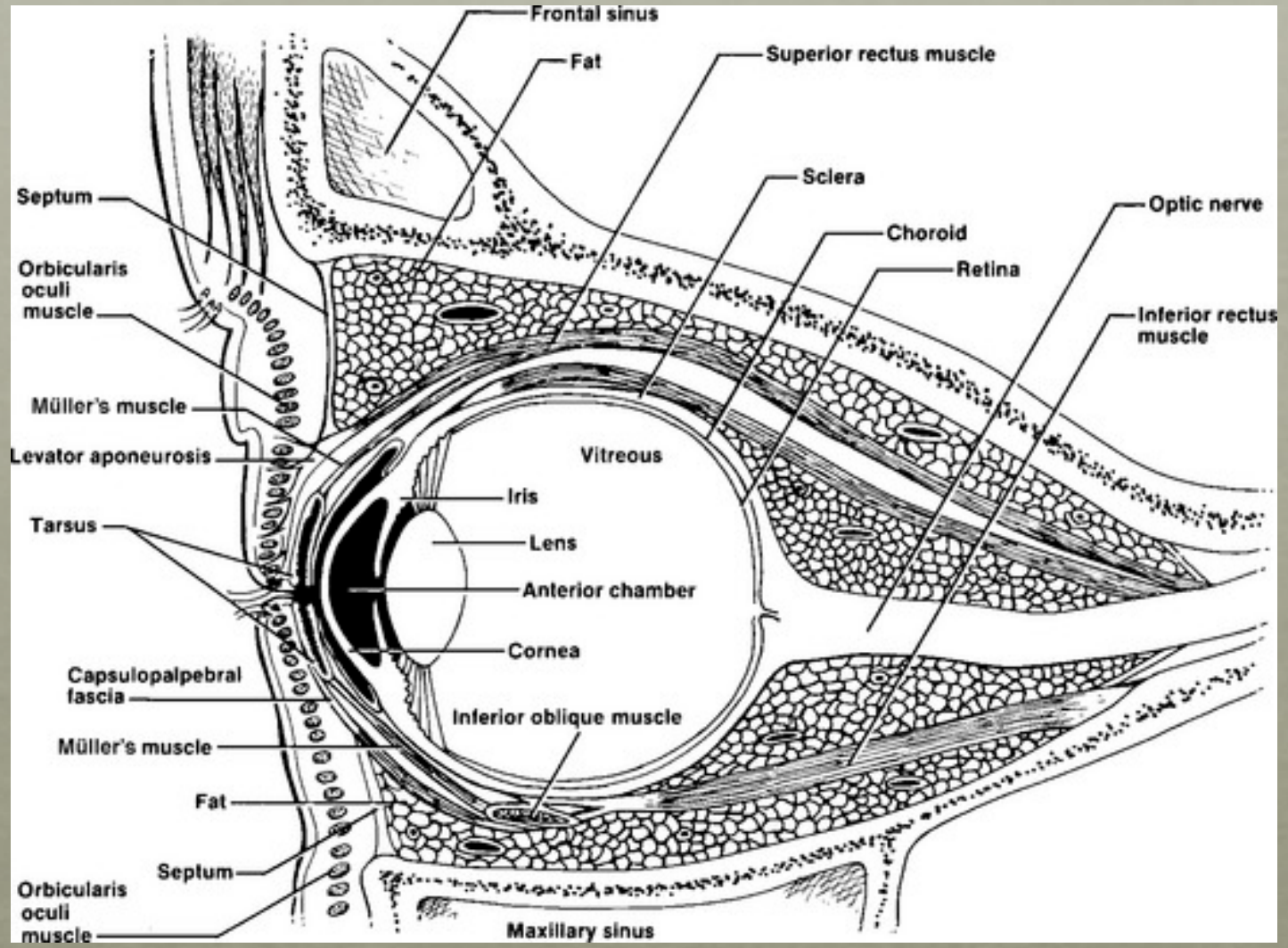

General Anesthetic
Glaucoma Surgery

- LMA/GET
- Maintain systemic blood pressure and optic nerve perfusion
- pCO2 concentration effect on choroidal venous pressure
- A decrease in the partial pressure of CO_2 has been associated with decreased choroidal volume and lower IOP in adults under general anesthesia.
  - Samuel JR, Beaugie´ A. Effect of carbon dioxide on the intraocular pressure in man during general anaesthesia. Br J Ophthalmol. 1974;58(1):62e7 urology nitrous Perkins
  - Hvidberg A, Kessing S, Fernandes A. Effect of changes in PCO2 and body position on intraocular pressure. Acta Ophthalmol. 1981;59(4):465e75
- Strategy to limit valsalva and bucking during emergence from anesthesia

PEDIATRIC GLAUCOMA

- GET/LMA
- Frequently bilateral
  - Break down room and rescrub
- Accurate IOP measurement
- Ketamine less IOP effect than sevoflurane
  - The Effects of Sevoflurane and Ketamine on Intraocular Pressure in Children During Examination Under Anesthesia.
  - Blumberg D, et al.
  - Develop consistent technique to measure IOP at repeated EUA
- Oculo-cardiac reflex
  - Bridle sutures
  - Tube shunts
  - Grasping muscles for angle procedures.

FILTERING PROCEDURES
TRABECULECTOMY/EXPRESS SHUNT

- Topical
  - Lidocaine gel
  - Proparacaine
- Intracameral
  - Discomfort from iris contact or PI
  - Non-preserved 1% - 4% lidocaine
- Sub-Tenon's infiltration
  - Conjunctival incision
  - Non-preserved lidocaine
  - With conjunctival dissection

FILTERING PROCEDURES
TRABECULECTOMY/EXPRESS SHUNT

- Retrobulbar, peribulbar block
  - Infiltration may lead to loss of nerve transmission
- GET
- No evidence that type anesthesia type has effect on post-operative success or final IOP
  - Geffen N, Carrillo MM, Jin Y, Trope GE, Buys YM. Effect of local anesthesia on trabeculectomy success. J Glaucoma 2008 Dec;17(8):658-661.

Tube Shunt Insertion

- Similar considerations as filtration surgery
- Posterior dissection with muscle manipulation
  - More with Baerveldt vs Ahmed
  - Oculo-cardiac reflex
  - Discomfort with tube insertion

SUPRACHOROIDAL HEMORRHAGE

- Intraoperative or perioperative
  - Rupture of atherosclerotic choroidal blood vessels
  - Pain, increased blood pressure, increased heart rate
- High IOP to very low IOP
  - Open eye during surgery then low post-op IOP after procedure
  - Older patients with atherosclerotic vascular disease

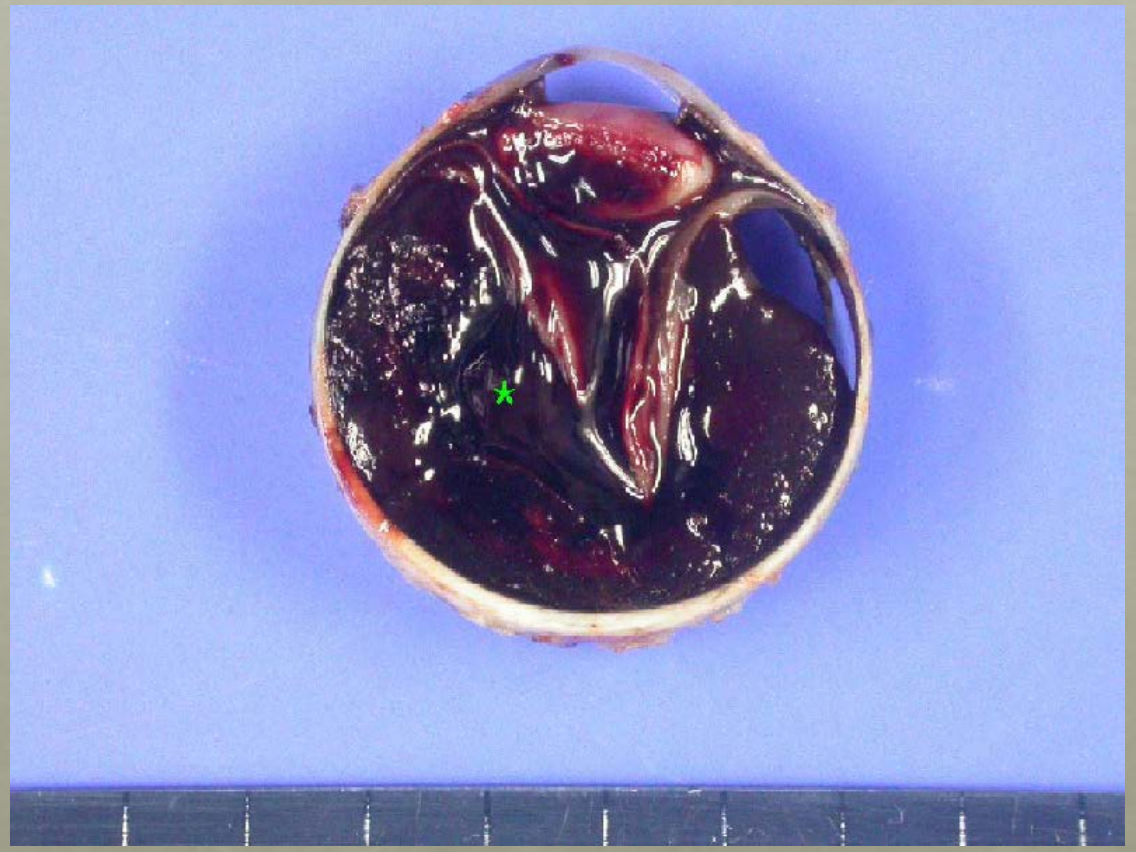

Korean J Ophthalmol. 2007 Mar;21(1):61-64. English.

SUPRACHOROIDAL HEMORRHAGE
INTERVENTIONS

- Control systemic blood pressure
  - Surrogate for fragile choroidal vessels

- "Uncontrolled hypertension may increase the risks of systemic and ophthalmic complications. However, there is insufficient evidence to support a specific value above which surgery should be deferred. Patients who are taking anti-hypertensive medication should continue their drugs up to and including the day of surgery. Rapidly lowering BP immediately prior to surgery is not advised".
  - Royal College of Ophthalmologists & Royal College of Anaesthetists. Local Anaesthesia for Ophthalmic Surgery. (Internet). London, 2012 Feb. p. 38.

- Reverse trendelenberg positioning
- Slowly reduce IOP prior to surgery/incision
- Hyperventilation
  - Decrease pCO2 and choroidal blood volume
- Squeezing/bucking/coughing

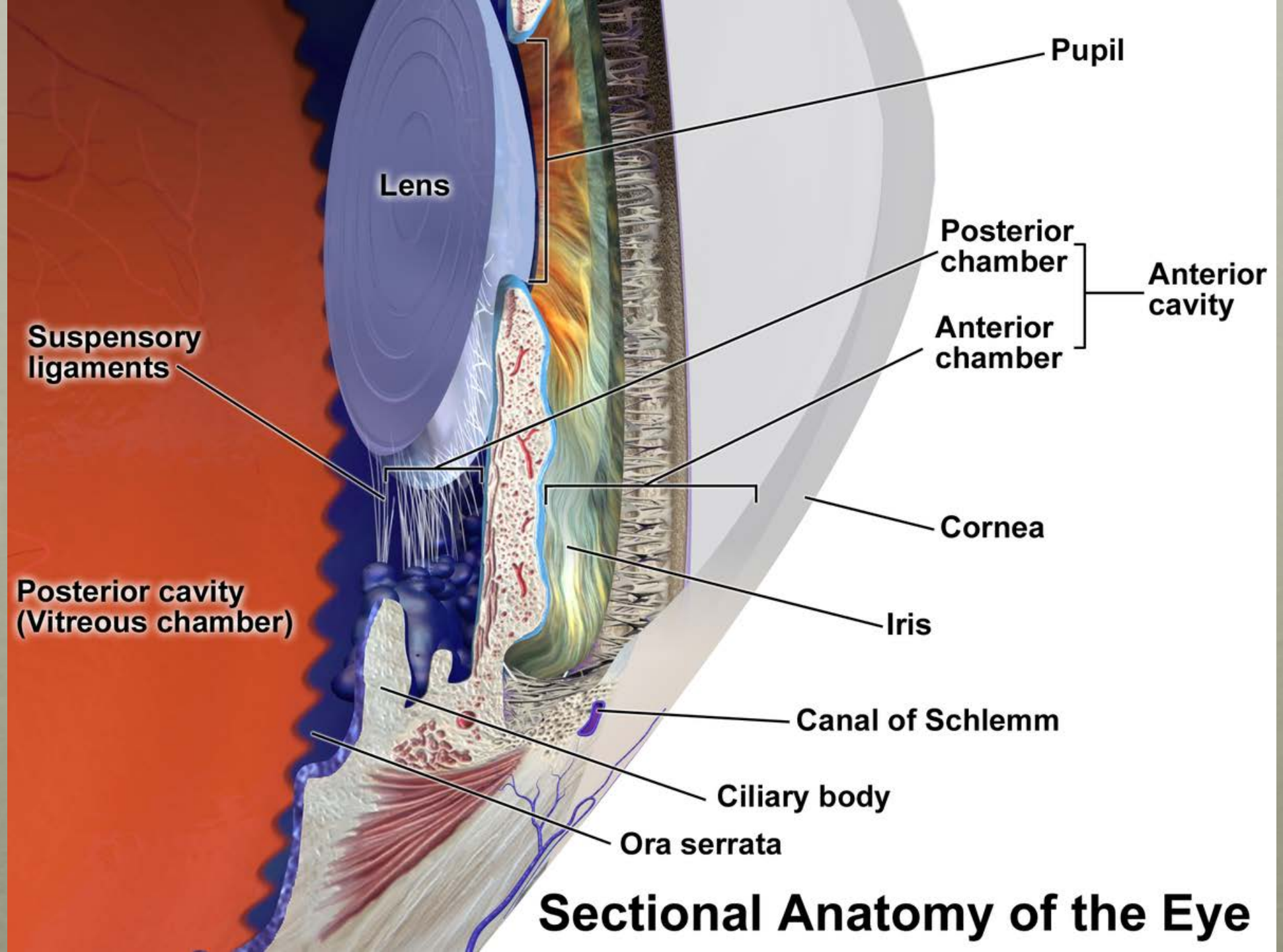
Pupil
Lens
Posterior chamber
Anterior cavity
Anterior chamber
Suspensory ligaments
Cornea
Posterior cavity (Vitreous chamber)
Iris
Canal of Schlemm
Ciliary body
Ora serrata
Sectional Anatomy of the Eye

ANGLE BASED PROCEDURES

- Trabecular meshwork and Schlemm's canal
  - iStent
  - Hydrus
  - Trabectome
  - GATT
  - Ab interno canaloplasty

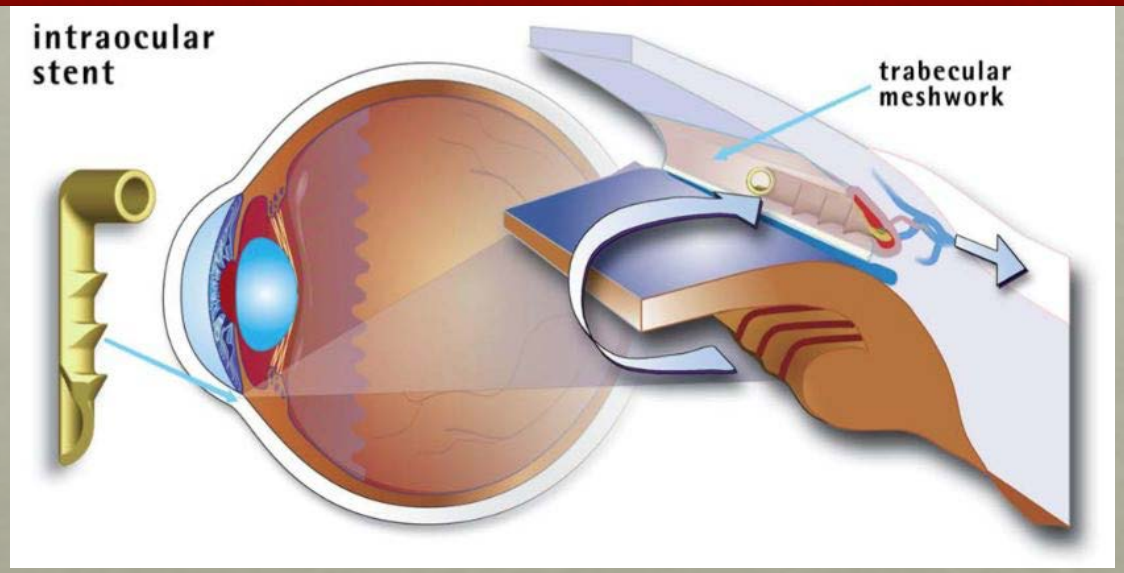

- Suprachoroidal space
  - Cypass
    - Mild discomfort with insertion
    - Reported oculo-cardiac reflex

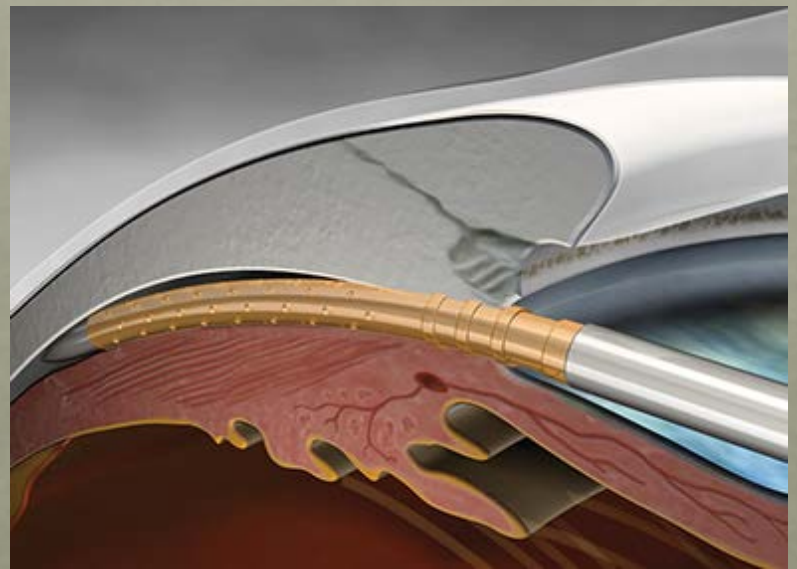

ANGLE BASED PROCEDURES

- InnFocus Micro Shunt
  - Subconjunctiva to anterior chamber
- Xen45 Gel Stent
  - Anterior chamber to subconjunctival space
    - Ab interno

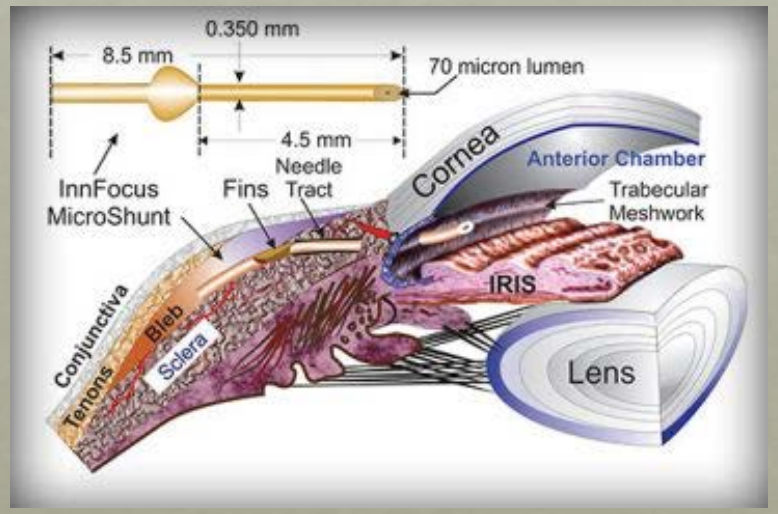

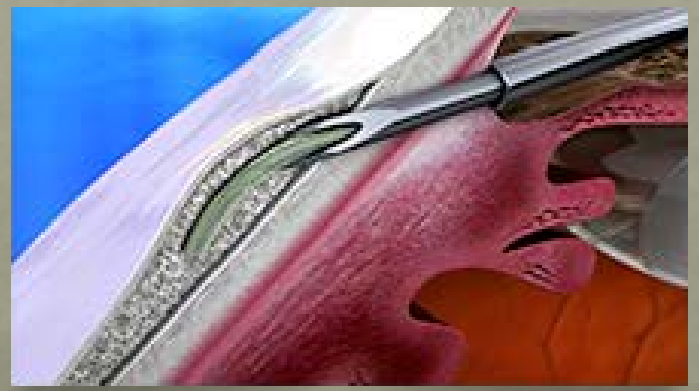

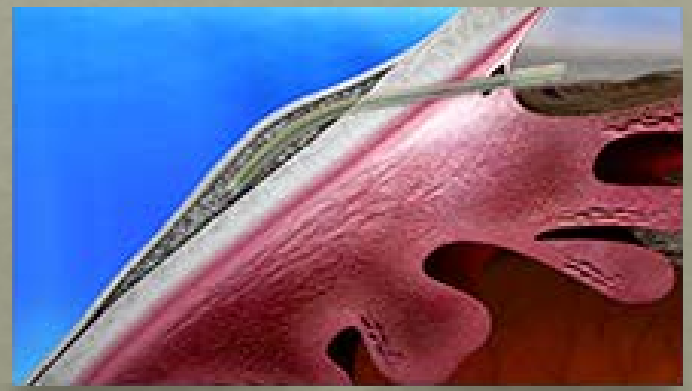

CYCLODESTRUCTIVE PROCEDURES

- Cyclocryotherapy
- Cyclophotocoagulation
- Endocyclophotocoagulation
  - ECP
  - Combination of sedation and RBB
  - SubTenon's corticosteroid

COMBINED PROCEDURES

- Phaco +
  - iStent
  - Cypass
  - ECP
  - GATT
  - Trab/Express shunt
  - Tube insertion
  - Avoid eye pressure after LA
    - No Honan Balloon or ocular massage after LA

COMBINED PROCEDURES

- Longer procedure time
- May require manipulation of patient/microscope position

Post-procedure pain control
Glaucoma surgery

- Most procedures have little to no post-operative pain
  - Cyclodestructive with most discomfort
  - Residual local anesthetic agent
- Pain as an indicator
  - Call if more than Tylenol or ibuprofen
- No routine prescription for opiod pain meds

REVIEW

- Pertinent ocular and orbital anatomy
- The glaucoma damaged optic nerve
- Pre-operative factors
- Modification of common methods of ocular anesthesia
- Considerations for specific procedures

THANK YOU!

- Questions?